

## Habit Breaking Appliance For Tongue Thrusting - A Modification

### Abstract

Tongue thrust, otherwise known as an infantile or reverse swallow pattern, refers to a swallowing movement where the tongue moves forward to approximate the lower lip. Amongst fixed habit breaking appliances for tongue thrust, crib is the most popular appliance. Invariably after few weeks of fixation of this appliance, due to biting forces in the anterior region the whole appliances sinks superiorly and either impinges on mucosa or gets submerged under it. A modification of the tongue crib has been suggested to overcome this problem.

### Key Words

Anterior Open-bite, Tongue Thrust, Malocclusion, Tongue Crib modification

<sup>1</sup> Sohinderjit Singh

<sup>2</sup> Prerna

<sup>3</sup> Parminder Dua

<sup>4</sup> Saurabh Jain

<sup>1</sup> Prof. & Head, Department Of Orthodontics

<sup>2</sup> Former Prof. & head, Department Of Periodontics

<sup>3</sup> Reader, Department of Pedodontics

<sup>4</sup> Reader, Department Of Orthodontics  
Himachal Institute of Dental Sciences, Poanta Sahib

### Address For Correspondence:

Dr Sohinderjit Singh, Deptt of Orthodontics  
HIDS, Poanta Sahib, Distt Sirmour H.P.

Date of Submission : 12/03/2011

Date of Acceptance : 28/08/2011

### Introduction

Tongue thrust, also known as an infantile or reverse swallow pattern, refers to a swallowing movement where the tongue moves forward to approximate the lower lip. It has been taken as one of the possible etiologic factors in malocclusion since early 1960s. Tongue thrusting, simply defined, is the habit of thrusting the tongue forward against the teeth or in between while swallowing. During infantile swallow the infant places the tongue beneath the nipple, in contact with the lower lip and swallow with the jaws apart and lips together. In contrast, during a normal swallow, the middle part of the tongue will press up and out on the roof of the mouth. Where the tip of the tongue is held during the swallow varies from the back side of the lower incisors to the papilla behind the upper incisors. Normal swallow does not include placing the tongue between the teeth even momentarily.

The infantile swallow shifts to an adult swallow gradually. This transition is commonly seen at 3-10 years of age. The full adult swallow can be observed as early as 3-4 years of age and is usually present by age 9 or 10<sup>23</sup>. In 10-15 % of typical population this is never achieved<sup>4</sup>. Presence of thumb sucking habit in a child may delay this transition. Adult swallow pattern will not get corrected in these individuals unless sucking habit is corrected.

During a tongue thrust, the mid-portion of the tongue is not pressed against the roof of

the mouth, but is employed down and forward while the tip of the tongue is spread out between the teeth and touching the lips momentarily. Therefore during the tongue thrust, the mid-portion of the tongue is not on the roof of the mouth and exerts little force against the palate. It's the constriction of the middle of the tongue that protrudes it. The tongue protrudes during swallowing in a tongue thrust. Swallowing occurs about 2000 times per day. During each swallow, the tongue can exert momentary pressures of 1 to 6 pounds on the surrounding structures of the mouth. This pressure will push the teeth and bone forward or apart. Tongue thrusting will move teeth into abnormal positions and cause growth distortions of the face and teeth. It means no simple cause-and-effect relationship between tongue thrust and open-bite. Proffit & Mason measured the data of the force, duration, intensity, and frequency of tongue thrust and concluded that the tongue thrust habit may sustain an open-bite instead of create one<sup>4</sup>. The individuals who place the tongue tip forward have less tongue force against the teeth than those who keep the tongue tip back<sup>5</sup>. It is rare that the anterior open-bite in an adolescent is solely the result of some habit, or the open-bite will correct spontaneously if the habit can be corrected. Pressure by tongue thrust swallowing lasts for approximately 1 second and is too short duration to affect the equilibrium. When there is an open-bite, a tongue thrust is a necessary physiologic adaptation to form an

anterior seal during swallowing to prevent food or liquids from escaping. Nearly every patient with an open-bite also has a tongue thrust swallow and the reverse is not true. Proffit concluded a child who has an open-bite, tongue posture may be a factor, but the tongue activity during swallowing is not<sup>6</sup>. Chawla et al observed that tongue thrust may develop during fixed appliance therapy<sup>7</sup>. The leveling and aligning phase of fixed mechanotherapy is commonly followed by bite opening as the next phase of tooth movement. Leveling can sometimes lead to a transient increase in overjet when the bite may be over closed pretreatment due to severely retroclined upper anterior teeth. In many situations, as a result of the bite-opening or transient increase in overjet during the early phases of treatment, tongue thrust develops as a secondary feature, though it was not present pretreatment. Thus, even though it may not be a cause of the original presenting malocclusion, a tongue thrust, which develops mid-treatment in this fashion may slow down the treatment and may start to tell on the anchorage. In the majority of cases, it may go unnoticed and anchor loss may continue unchecked. The problem is certainly an added difficulty in managing high mandibular plane angle cases. Additionally, tongue thrust and open bite problems are more common and more difficult to treat in high mandibular plane angle cases<sup>7</sup>.

## EFFECTS

There are several different types of tongue thrust and resultant orthodontic problems:

- **Anterior open bite** - the most common and typical type of tongue thrust. In this case, the front lips do not close and the child often has his mouth open with the tongue protruding beyond the lips. In general, it has been noted that a large tongue usually accompanies this type of tongue thrust.
- **Anterior thrust** - upper incisors are extremely protruded and the lower incisors are pulled in by the lower lip. This particular type of thrust is most generally accompanied by a strong mentalis (muscle of the chin).
- **Unilateral thrust** - the bite is characteristically open on the thrust side.
- **Bilateral thrust** - the anterior bite is closed; however the posterior teeth from the first bicuspid to the back molars may be open on both sides. This is the most difficult thrust to correct.
- **Bilateral anterior open bite** - the only teeth that touch are the molars with the bite completely open on both sides including the anterior teeth. Once again a large tongue is also noted.
- **Closed bite thrust** - typically shows a double protrusion meaning that both the upper and lower teeth are flared out and spread apart.

## Management

Often other myofunctional variables are associated with the tongue thrust, all of which may lead to dentofacial developmental differences that could have negative dental, speech, and psychosocial consequences. Management of the tongue thrust, therefore, requires a team approach and may include a dentist, orthodontist, physician, and a speech pathologist. Variables that must be addressed by the team sometimes include: (a) anatomical differences (high narrow palatal vaults, malocclusions, restricted frenulums, and lip incompetencies), (b) oral behaviors (thumb/finger/pacifier sucking, licking the lips, teeth grinding, and mouth breathing), (c) medical conditions (obstructions to the airway, and upper respiratory complications), and (d) associated speech problems (lalling and lisping behaviors).

Interceptive attempts to contain tongue thrust have conventionally involved suggestions to the patient, myofunctional exercises and appliances such as cribs, rakes, overlay bite plates, interocclusal elastics, maxillary expanders and loose fitting training appliances. Myofunctional

therapy is indicated in severe situations as soon as the child is able to understand the problem and cooperate with the therapist. Often the orthodontist can instruct the child in the proper way of swallowing and this knowledge, coupled with changes in the relationships of teeth during orthodontic treatment, can correct the problem. Increased patient awareness of occlusion also aids in controlling tongue thrust in swallowing and speaking.

Tongue thrust may contribute to poor occlusal intercuspation both during and after treatment. A tongue thrust may also develop during orthodontic mechanotherapy as a result of the transient creation of intra and interarch spaces and this little recognized phenomenon has been found to occur in many randomly followed cases. In many instances, this seemingly adaptive and secondary response of the tongue posture and function may persist and thereafter impede the resolution of intra and interarch problems. During treatment with fixed appliances, especially so with the preadjusted appliance, anchorage preservation is very important to avoid treatment compromises and even failures. In cases where anchorage preservation is critical, any additional factor that tends to tax the anchorage, however small its individual influence, may cumulatively impact the treatment outcome and thus its role becomes important.

## Appliances

There are two types of appliances for correction of tongue thrust habit: removable and fixed. Fixed appliances are always preferred, because the outcome is less dependent on patient's cooperation. Amongst fixed appliances, fixed tongue crib is the most popular appliance (**Fig 1**).

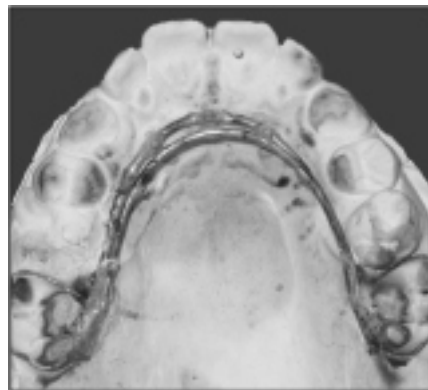


Fig. 1 Basic tongue crib Design

In addition, this appliance can also be used during fixed orthodontic treatment in those cases that have pre-existing thrusting

or those cases that develop it during treatment. Fixed tongue crib should be used with lots of caution during fixed orthodontic phase. It is recommended that if this appliance is to be used during fixed orthodontic treatment, any mechanism which is likely to tax anchorage should be withheld till the time the habit gets controlled or corrected. Otherwise, an anterior tongue pressure on crib during its thrust gets transmitted on to the molars. It slows down the treatment and may start to tell on the anchorage. In the majority of cases, it may go unnoticed and anchor loss may continue unchecked.

## Fixed tongue cribs: mechanism of action

The tongue crib quickly redirects the tongue to a more normal swallowing position for the patients that thrust their tongue in a forward position<sup>8</sup>. The mid portion of the tongue is forced backwards and up because if the patient parts the teeth to swallow, the wires of the appliance are moved downward off the roof of the mouth into a position where the tongue will be engaged if the tongue moves out between the lips. For this reason the patient should be instructed to keep the tip of the tongue under the wires during the swallow and concentrate on pressing the back half of the tongue against the palate.

The appliance is cemented in place and will usually stop the habit in the first couple of months and need to keep the appliance in place until the permanent front teeth overlap each other. After the tongue crib is removed, a retainer will need to be worn (full time for the first 6-8 months followed by part time wear at night only for another 6-8 months). Cayley AS et al. performed a prospective clinical study and assessed the effect of tongue re-education therapy on tongue function and dentofacial form in anterior open-bite patients using electropalatography and lateral head cephalometric radiographs.<sup>9</sup> She concluded that there was some evidence of a trend for eruption of upper and lower incisors with concomitant reduction of the anterior open-bite and implied that the therapy was partially successful in improving tongue function during swallowing and in reducing anterior open-bite.

## The Design And The Modification

The most common design of fixed anti-tongue thrust appliance has two .036" SS base wires which are adapted, one from upper first molar band on working model on one side to the first molar band on the other side. Anterior extension of this wire is up to

the incisive papilla. The second wire is adapted in such a way that it comes in contact with the first base wire posteriorly in 2<sup>nd</sup> premolar region (Fig 1).

Anterior portion of this wire is fabricated in such a way that it lies behind cinguli of lower incisors (Fig 2).

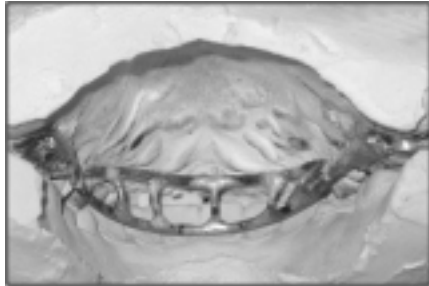


Fig. 2 Lingual view of Occluded working models

It is ensured that these wires do not interfere with the lower teeth during occlusion. These two base wires are interconnected with each other by multiple cross wires soldered on both sides. The purpose of this design is to hold the tongue behind incisors during swallowing. Since the fabrication process involves multiple soldered joints, the base wires get softened. However, after few weeks of its cementation of this appliance in the patient's mouth, due to biting forces in the anterior region, the whole appliances sinks superiorly and either impinges on mucosa or gets submerged under it. Patient presents to the dentist's office with pain and inflammation around the anterior part of the palate adjacent to first base wire. At this stage the clinician would remove this appliance from patient's mouth by decementing molar bands. Then the appliance is arbitrarily adjusted occlusally and cemented again in patient's mouth. This may have to be repeated many times during treatment. Moreover, during these adjustments, invariably the appliance gets further disoriented and needs to be modified again. Therefore, the conventional design requires extra visits to the dentist; more chair time in addition to patient discomfort. To overcome this problem we modified the design of the conventional crib appliance. During its fabrication prior to removal from the working cast, following soldering, cold mould seal is applied under the base wire and then cold cure acrylic is sprinkled on it so as to increase the surface area of the base wire. Usually 2-3 mm extensions of acrylic on either side are sufficient to prevent it from sinking (Fig. 3).

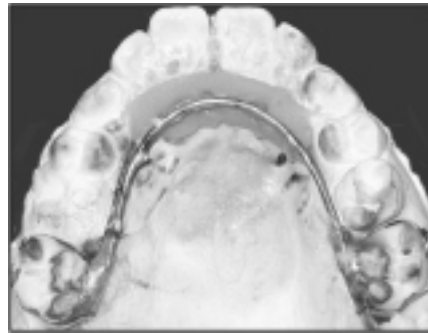


Fig. 3 Extension of cold cure acrylic on base wire

Care is taken not to burn the plaster under the base wire during soldering. This is made possible by inserting a metal foil under the base wire prior to soldering. In addition keep a cotton ball soaked in water, on the foil next to the working area to prevent it from overheating. Appliance is removed from the cast; metal and acrylic parts are finished and polished (Fig. 4).

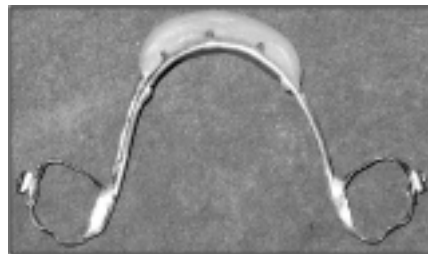


Fig. 4 Finished modified Tongue Crib prior to trial fit

Appliance is positioned in the patient's mouth for trial fit (Fig. 5).

Minor discrepancy if any in the acrylic can be adjusted by trimming it. Since with this design the contact area between mucosa and the appliance increases manifold, it is less likely to get distorted and embedded. Clinically there is better patient comfort and cooperation and lesser number of appliance adjustments.

#### REFERENCES

1. Pinkham JR et al. Pediatric dentistry:

infancy through adolescence, 2nd ed. WBSaunders Co, Philadelphia, 1994; pp205-6,371-2.

2. Graber TM. Orthodontics, principles and practice, 3rd ed. WB Saunders Co, Philadelphia, 1972; pp168
3. Kharbanda et al. Oral habits in school going children of Delhi. Journal of Ind Soc Pedod Prev Dent 2003; 21(3): 120-4.
4. Proffit WR, Mason RM. Myofunctional therapy for tongue thrusting: background and recommendations. J Am Dent Assoc 1975; 90: 403-11.
5. Proffit WR. Lingual pressure patterns in the transition from tongue thrust to adult swallowing. Arch Oral Biol 1972; 17:555-63.
6. Proffit WR. Contemporary orthodontics. Lst ed. Mosby-Year Book, Inc., 1986; pp110-2.
7. Chawla HS, Suri S, Utreja A. Is tongue thrust that develops during orthodontic treatment an unrecognized potential road block?. J Indian Soc Pedod Prev Dent 2006; 24:80-3
8. McDonald RE, Avery DR. Dentistry for child and adolescent 6th ed., Mosby Co., St. Louis, 1994; pp782-4.
9. Cayley AS et al. Electropalatographic and cephalometric assessment of myofunctional therapy in open-bite subjects. Aust Orthod J 2000; 16(1): 23-33.
10. McDonald RE, Avery DR. Dentistry for child and adolescent 6th ed., Mosby Co., St. Louis, 1994; pp782-4.
11. Graber TM, Vanarsdall RL. Orthodontics, current principles and techniques, 2nd ed. Mosby-Year Book, Inc., St. Louis, 1994; pp17, 43-44.
12. Bell WH et al. Surgical correction of dentofacial deformities. WB Saunders Co, Philadelphia, 1980; pp113.

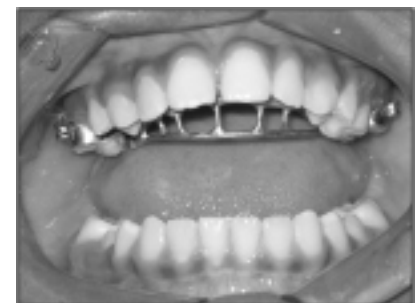
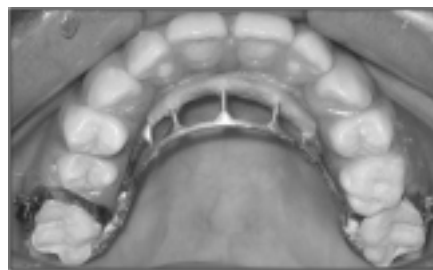
Fig 5 Modified tongue crib appliance in Patient's mouth